

Hypoxaemia during one-lung anaesthesia



Alexander Ng MB ChB DA(UK) FRCA MD
Justiaan Swanevelder MB ChB FRCA FCA(SA) MMed

Key points

During one-lung ventilation (OLV), ventilation–perfusion mismatch leads to increases in shunt and dead space.

Lung isolation is achieved by correct placement of a double-lumen endobronchial tube or an endobronchial blocker.

Hypoxaemia can occur rapidly during OLV.

Administer 100% oxygen, ventilate both lungs, and check airway device if profound hypoxaemia develops.

Tension pneumothorax in either lung is a rare but serious cause of hypoxaemia.

Hypoxaemia is an adverse but inevitable consequence of one-lung ventilation (OLV). This article reviews the indications for lung isolation, elucidates why hypoxaemia occurs, and explains the relationship between developments in methods of lung isolation and attenuation of hypoxaemia. Recent advances in endobronchial blockers and strategies for prompt management of hypoxaemia are described.

Indications

Lung isolation is necessary for:

- facilitating surgery, for example, lobectomy, pneumonectomy, pleurectomy, decortication, bullectomy, diaphragmatic hernia repair, pericardial window, and oesophagectomy;
- preventing cross-contamination of the contralateral lung, for example, endobronchial haemorrhage, abscess with empyema, bronchiectasis, and lavage;
- controlling distribution of ventilation, for example, bronchopleural fistula.

Surgery is considered to be a relative indication, whereas the latter two would be absolute indications for lung isolation. In some patients, for example, those with lung abscess or bronchopleural fistula who may require surgery, there may be a combination of indications for lung isolation.

Pathophysiology of hypoxaemia

Patients who require OLV for thoracic surgery are placed in the lateral decubitus position. The lower, dependent lung is ventilated, whereas the upper, non-dependent lung is allowed to collapse when opening the chest. Factors predictive of hypoxaemia during OLV include: ventilation of the left rather than the right lung, low oxygen partial pressure on two lungs, absence of reduction of perfusion to areas of lung pathology, and supine position rather than the lateral decubitus position.¹

doi:10.1093/bjaceaccp/mkq019

Development of hypoxaemia (i.e. arterial oxygenation <90%) caused by OLV may be explained by considering oxygen storage, dissociation of oxygen from haemoglobin, the relationship between ventilation and perfusion, and factors that reduce the effect of hypoxic pulmonary vasoconstriction.

Oxygen storage, oxygenation, and ventilation

Patients are susceptible to hypoxaemia owing to a reduction in the functional residual capacity and oxygen storage during OLV, in addition to the effects of anaesthesia and the lateral decubitus position. Atelectasis in the ventilated dependent lung occurs as a result of:

- compression caused by the weight of the mediastinum;
- compression by abdominal contents after diaphragmatic muscle relaxation;
- increased closure of small airways with old age, reduced elastic recoil, and the lateral decubitus rather than the erect position.

Dissociation of oxygen from haemoglobin

During OLV, there is a reduction in arterial oxygen partial pressure and also permissive hypercarbia and respiratory acidosis. These physiological changes lead to rapid dissociation of oxygen from haemoglobin (Bohr effect), as shown by the steep slope of the oxygen haemoglobin dissociation curve.

Ventilation–perfusion relationship

Abnormalities of ventilation and perfusion of the respiratory system may be considered in three situations:

- Spontaneous ventilation.
When the patient is breathing spontaneously, ventilation, under negative pressure, is greater in the dependent lung

Alexander Ng MB ChB DA(UK) FRCA MD

Consultant Anaesthetist
Heart and Lung Centre
Royal Wolverhampton Hospitals NHS
Trust and University of Birmingham
West Midlands WV10 0QP
UK
Tel: +44 1902 307999
Fax: +44 1902 694352
E-mail: alexander.ng@rwh-trnhs.uk
(for correspondence)

Justiaan Swanevelder MB ChB FRCA
FCA(SA) MMed

Consultant Anaesthetist
Glenfield Hospital
University Hospitals of Leicester NHS
Trust
Leicester LE3 9QP
UK

than in the non-dependent lung (except at the very bottom of the dependent lung). Similarly, perfusion in the dependent lung is greater than that in the non-dependent lung. Thus, the ventilation–perfusion relationship is normal and is similar to that observed if the patient is sitting in the standard upright position (Fig. 1A).

- Positive pressure ventilation with two lungs.

The relationship of ventilation and perfusion changes when the patient is paralysed. In this situation, positive pressure ventilation is directed preferentially to the non-dependent lung, whereas perfusion remains greater in the dependent lung than in the non-dependent lung (Fig. 1B). Thus, compared with spontaneous ventilation, positive pressure ventilation leads to an increase in areas of lung with low ventilation–perfusion ratios. The volume of dead space, that is to say, ventilated lung with no perfusion, also increases during positive pressure ventilation; this effect contributes to hypercarbia.

- Positive pressure ventilation to one lung.

During OLV, when the non-dependent lung is not ventilated, some perfusion still remains in this lung, despite hypoxic pulmonary vasoconstriction (Fig. 1C). Thus, there may be a substantial increase in shunt and hence hypoxaemia.

during OLV. This effect occurs when there is a reduction in alveolar partial pressure of oxygen to between 4 and 8 kPa. Factors that impair hypoxic pulmonary vasoconstriction in the non-ventilated lung and hence promote hypoxaemia during OLV include:

- Increase in pulmonary artery pressure which may occur when:
 - there is an increase in pulmonary vascular resistance caused by atelectasis in the ventilated lung;
 - excessive positive end-expiratory pressure is applied or develops intrinsically in the ventilated lung. There is a diversion of blood to the non-ventilated lung;
 - vasoconstrictor drugs, for example, phenylephrine and epinephrine, are administered.
- Supine position. In this position, the vertical height of the lungs is less than in the lateral decubitus or erect position. This reduction of height allows blood flow to a greater proportion of unventilated collapsed lung, thus attenuating hypoxic pulmonary vasoconstriction.
- Failure of lung collapse. Provided there are no adhesions, the unventilated non-dependent lung should collapse when the chest wall is open to the atmosphere. If this unventilated lung is held partially open, then intrapleural pressure becomes increasingly negative during inspiration. This effect leads to an increase in transpulmonary pressure (i.e. the pressure difference between alveoli and pleura) and hence distension of extra-alveolar pulmonary vessels that oppose hypoxic pulmonary vasoconstriction in the non-ventilated lung.
- Vasodilators, for example, calcium antagonists, sodium nitroprusside, nitrates, α -antagonists, inhalation anaesthetic agents, and endogenous prostaglandins, released during lung handling.

Hypoxic pulmonary vasoconstriction

Hypoxic pulmonary vasoconstriction in the extra-alveolar pulmonary arterioles supplying the unventilated lung is an essential physiological response to minimize shunt and hence hypoxaemia

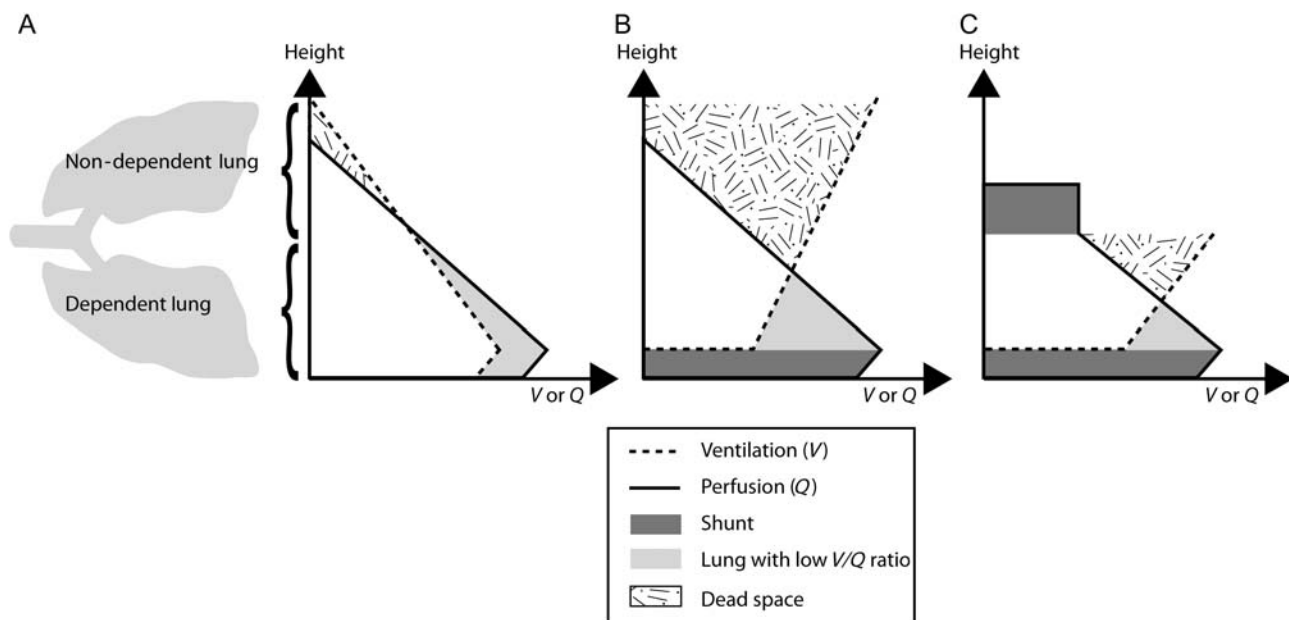


Fig 1 Schematic diagrams showing ventilation–perfusion relationship in the lateral decubitus position during: (A) spontaneous ventilation, with two lungs, (B) positive pressure ventilation to both lungs, and (C) positive pressure ventilation to the dependent lung.

Methods used for lung isolation

There are two main methods for lung isolation: use of a double-lumen endobronchial tube or insertion of an endobronchial blocker.

Double-lumen endobronchial tubes

Features

Modern-day double-lumen endobronchial tubes have the following features. They allow:

- collapse of either the left or right lung to assist surgery;
- airway toilet;
- left or right lung isolation to prevent cross-contamination;
- ventilation of the left lung;
- ventilation of the right lung, including its upper lobe;
- surgical access for any lung resection, including sleeve resection and pneumonectomy.

Development

In the early days of thoracic anaesthesia, the previously mentioned features were not available, and hypoxaemia was a significant problem. To understand the relative safety of modern-day double-lumen endobronchial tubes, it is necessary to analyse the relationship between historical tube designs and risk of hypoxaemia. The following types of tubes were historically utilized in thoracic anaesthesia:

- Single-lumen endobronchial tube with a carinal cuff. This design by Gale and Waters in 1932 had several problems related to hypoxaemia, that is to say, dislodgement, difficulty with suctioning, and inability to ventilate the right upper lobe. Also, lung collapse was slow.
- Single-lumen endobronchial tubes with a tracheal cuff and an endobronchial cuff. This tube design comprised two cuffs that allowed selective lung ventilation. However, the risk of hypoxaemia was high owing to difficulty with airway toilet and also to the inability to

ventilate the right upper lobe. Historical examples were the Magill (1935) and the Mackintosh Leatherdale (1955) endobronchial tubes which were suitable for ventilation of the left lung. The problem with ventilation of the right upper lobe was overcome by the Gordon Green endobronchial tube (1955). This design contained a slotted endobronchial cuff, allowing ventilation and hence oxygenation of the right upper lobe, in addition to the right middle and lower lobes. This tube also consisted of a carinal hook that was designed to improve the accuracy of blind positioning and hence ventilation.

- Early double-lumen endobronchial tubes featuring an endobronchial lumen with an endobronchial cuff and a tracheal lumen with a tracheal cuff.

This model permitted application of suction, but early versions called the Carlens tube with a carinal hook (1949) and the Bryce Smith tube without a carinal hook (1959), were only suitable for left lung ventilation. Isolated right lung ventilation and oxygenation were not possible until the slotted cuff was incorporated into later designs, that is to say, the Bryce Smith Salt tube (1960) and White's modification of the Carlens tube (1960).

Early double-lumen endobronchial tubes had narrow lumens and high resistance to ventilation. Alterations took place to ameliorate these problems with the introduction of the Robertshaw design in 1962. Both left- and right-sided tubes were available.

Selection of double-lumen tubes

Modern-day double-lumen endobronchial tubes are based on the Robertshaw design. In the current practice, there are two main types of double-lumen endobronchial tubes:

- plastic type, for example, the Broncho-Cath (Mallinckrodt, Tyco Healthcare). For adults, the standard sizes are 35, 37, 39, and 41 Fr. Other companies, for example, Rusch and Sheridan, manufacture this type of tube as well.
- disposable Robertshaw (Phoenix Medical). The Robertshaw tube (Fig. 2A) comes in small, medium, or large sizes.

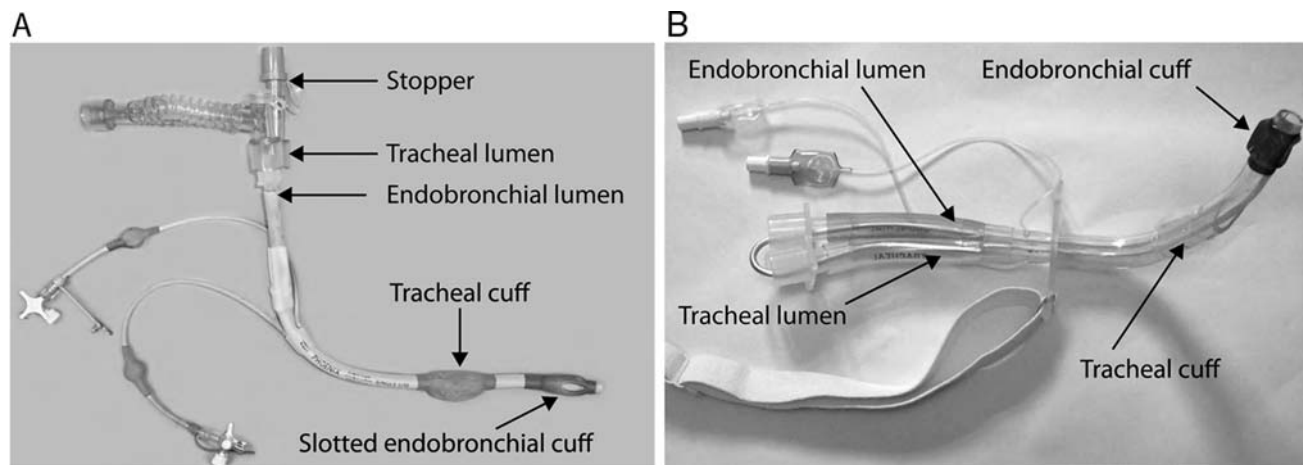


Fig 2 Types of double-lumen tubes: (A) right-sided Robertshaw double-lumen tube and (B) left-sided Rusch double-lumen tracheostomy tube.

It has been found that the orifice within the slotted cuff ('Murphy's eye') for the right-sided Robertshaw double-lumen endobronchial tube enlarges with cuff inflation whereas that for right-sided plastic double-lumen tubes does not do so. In theory, therefore, the risk of hypoxaemia during right-lung ventilation may be minimized by the right-sided Robertshaw design.

A double-lumen endobronchial tube of appropriate size should be selected for patient height, gender, and size of main stem bronchi.² Owing to the marked variation in bronchial dimensions and in double-lumen endobronchial tubes of the same nominal size from different manufacturers, strict guidance cannot be given for selection of size of the tube. In general, small tube sizes are appropriate for females since the diameter of their cricoid cartilage is smaller than that of males. Depending on the type of surgery, either a left sized or right sized double-lumen endobronchial tube should be used.

Rarely, patients require OLV via a tracheostomy, for example, when they already have a tracheal stoma or because they have had lung resection and the bronchial stump requires protection from barotrauma during weaning from mechanical ventilation on the Critical Care Unit. Plastic double-lumen endobronchial tracheostomy tubes are available for this purpose, for example, Rusch Tracheopart (Fig. 2B).

Endobronchial blockers

In addition to double-lumen endobronchial tubes, endobronchial blockers may be utilized for OLV. Interest in their design and use has increased recently and a number of new models have become available. Endobronchial blockers consist of a balloon and a central lumen for application of suction and lung deflation or administration of oxygen. There are two main designs for endobronchial blockers:

- (i) Individual endobronchial blocker with:
 - (a) an adjustable monofilament loop at the tip, called the wire-guided Arndt[®] endobronchial blocker (Cook Critical Care, Bloomington, IN, USA). Sizes available are 5 and 9 F³ (Fig. 3A).
 - (b) fixed flexion at the tip (Coopdech[®] endobronchial blocker tube, Smiths Medical) (Fig. 3B). One size, equivalent to 9 F, is available.

- (c) adjustable flexion at the tip called the Cohen[®] Tip Deflecting Endobronchial Blocker (Cook Critical Care). There is one size of 9 F which is suitable for a tracheal tube of at least 7.5 mm in internal diameter.⁴

- (ii) Endobronchial blocker combined with a tracheal tube⁵ such as:

- (a) Univent[®] Torque Control Blocker (Vitald Ltd, Lewiston, NY, USA), consisting of a blocker with spherical balloon incorporated into a single-lumen tracheal tube whose internal diameter size range is from 3.5 to 9.0 mm. Except for size 3.5 mm, all tracheal tubes have a tracheal cuff (Fig. 3c).
- (b) an endobronchial blocker accompanying the Papworth Bivent tube which is a single cuffed, double-lumen tracheal tube with a central flange. The flange enables blind tube positioning on the carina and the side-by-side arrangement of each lumen *in situ* allows selective blind placement of a bronchial blocker to each lung as required. In contrast with double-lumen tubes discussed above, there is no endobronchial limb. As this system of lung isolation is new, further testing and results of clinical trials are awaited.⁶

When lung resection is not required, or if there are no issues with cross-contamination (e.g. pleural surgery, lung biopsy, and oesophagectomy), either a double-lumen tube or an endobronchial blocker may be utilized for OLV. In this situation, endobronchial blockers may be the preferred device. Examples include situations when:

- the patient is already intubated (with a single-lumen tracheal tube) before operation on the Critical Care Unit.
- the patient is to be ventilated after operation with a single-lumen tracheal tube.
- a double-lumen endobronchial tube is relatively short in very tall patients and thus easy lung isolation cannot be achieved.
- there is difficulty with laryngoscopy and hence placement of a double-lumen endobronchial tube.⁷
- minor airway injuries associated with double-lumen tubes are to be obviated. It has been shown in a randomized controlled




Fig 3 Endobronchial blockers: (A) Arndt[®] endobronchial blocker, (B) Coopdech[®] endobronchial blocker, and (C) Univent[®] Torque Control Blocker.

trial that postoperative hoarseness and vocal cord lesions occur significantly more frequently with double-lumen endobronchial tubes than with endobronchial blockers.⁸

Endobronchial blockers have a natural tendency to dislodge and cause airway obstruction. Hypoxaemia and cardiac arrest associated with malpositioning and airway obstruction have been reported.⁹

Strategies for management of hypoxaemia

There are two main strategies to manage hypoxaemia during OLV: prevention and treatment. Prevention of hypoxaemia may be achieved by ventilation of the patient's lungs with 100% oxygen with time for denitrogenation before OLV. Furthermore, prevention relates to issues of training and expert competency in methods of advanced airway management and ventilation in thoracic anaesthesia.

When profound hypoxaemia develops during OLV, it is necessary to treat the problem by increasing the inspired oxygen to 100% and, on some occasions, ventilating both lungs. Surgery may have to be discontinued whilst the problem is managed. The patient's lungs should be ventilated manually and checks should be performed. Strategies to manage hypoxaemia may be divided into three main categories: delivery of oxygen to the patient, treatment of causes associated with high airway pressure, and management of physiological hypoxaemia.

Delivery of oxygen

As with all anaesthetics, problems related to the anaesthetic machine and to the breathing system should be excluded (Table 1).

Causes associated with high airway pressure

Hypoxaemia may occur in the presence of high airway pressure. Causes include malposition of the airway device,¹⁰ blood and sputum in the airway, bronchospasm, dynamic hyperinflation, tension pneumothorax in either lung, and coughing. Prompt treatment of these problems is required (Table 1).

Physiological hypoxaemia

In the absence of these problems, hypoxaemia may be due to shunt and inadequate ventilation caused by OLV. In this situation, a number of strategies may be utilized to prevent further desaturation (Table 1); these include:

- (i) insufflation of oxygen to the non-ventilated lung to improve oxygenation of shunted blood.
- (ii) continuous positive airway pressure (with oxygen) to the non-ventilated lung to attenuate hypoxaemia of shunted blood. This technique of mild inflation to the operated lung is particularly well tolerated during decortication when it may optimize operative conditions.
- (iii) application of positive end-expiratory pressure to the dependent lung to improve functional residual capacity and hence oxygenation. However, excessive positive end-expiratory pressure may divert blood to the non-ventilated lung and exacerbate shunt and hence hypoxaemia.
- (iv) optimization of haemoglobin and cardiac output to improve oxygen delivery.

Table 1 Management of hypoxaemia during OLV

Problem area	Example	Action
Gas delivery	Anaesthetic machine, e.g. problem with oxygen supply Disconnection of breathing system	Check pipeline pressure and gas analyser Reconnection of breathing system
High airway pressure	Malposition of double-lumen tube causing incomplete lung ventilation	Reposition double-lumen tube, with bronchoscope if required
	Malposition of endobronchial blocker leading to airway obstruction	Deflate blocker, bronchoscope to reposition
	Sputum and blood	Suction
	Bronchospasm	Bronchodilators if needed
	Air trapping with dynamic hyperinflation	Decompress by disconnection of breathing system from tracheal tube
Physiological	Pneumothorax of the ventilated lung	Emergency decompression with surgical assistance
	Coughing due to inadequate muscle relaxation	Re-paralyse
	Shunt in non-ventilated lung	Oxygen insufflation to non-ventilated lung CPAP to non-ventilated lung Intermittent two-lung ventilation
		Encourage early clamping of pulmonary artery to non-ventilated lung (during planned lung resection)
		Optimize haemoglobin, cardiac output, and hence oxygen delivery
		If total lung collapse is not required and if prevention of cross-contamination is not an issue, the application of high-frequency jet ventilation to both lungs may be considered
	Reduction in functional residual capacity of ventilated lung due to weight of the mediastinum and abdominal contents in the lateral decubitus position	PEEP to ventilated lung
	Inadequate lung ventilation due to narrow lumen of double-lumen tube	Consider increase in driving pressure to ventilated lung

- (v) utilization of high-frequency jet ventilation¹¹ rather than conventional ventilation, provided complete lung collapse is not required. This technique requires total i.v. anaesthesia.
- (vi) pharmacological methods such as administration of nitric oxide and almitrine on an occasional basis.

In conclusion, hypoxaemia may occur at any time and with rapidity during OLV. Over the past 50 yr, we have seen improvements in design of double-lumen endobronchial tubes and of endobronchial blockers. Although OLV is a potentially hazardous anaesthetic technique, it may, with constant vigilance and experience, be administered safely.

Conflict of interest

None declared.

References

1. Karzai W, Schwarzkopf K. Hypoxaemia during one lung ventilation. *Anesthesiology* 2009; **110**: 1402–11
2. Joen Y, Ryu HG, Bahk JH, Jung CW, Goo JM. A new technique to determine the size of double-lumen endobronchial tubes by the two perpendicularly measured bronchial diameters. *Anaesth Intensive Care* 2005; **33**: 59–63
3. Narayanaswamy M, McRae K, Slinger P et al. Choosing a lung isolation device for thoracic surgery: a randomized trial of three bronchial blockers versus double-lumen tubes. *Anesth Analg* 2009; **108**: 1097–101
4. Cohen E. The Cohen flexitip endobronchial blocker: an alternative to a double lumen tube. *Anesth Analg* 2005; **101**: 1877–9
5. Campos JH, Kernstine KH. A comparison of a left-sided Broncho-Cath with the Torque Control Blocker Univent and the wire-guided blocker. *Anesth Analg* 2003; **96**: 283–9
6. Ghosh S, Klein AA, Prabhu M, Falter F, Arrowsmith JE. The Papworth BiVent tube: a feasibility study of a novel double-lumen endotracheal tube and bronchial blocker in human cadavers. *Br J Anaesth* 2008; **101**: 424–8
7. Ho CYA, Chen CY, Yang MW, Liu HP. Use of the Arndt wire-guided endobronchial blocker via nasal for one-lung ventilation in patient with anticipated restricted mouth opening for oesophagectomy. *Eur J Cardiothorac Surg* 2005; **28**: 174–5
8. Knoll HK, Ziegeler S, Schreiber JU et al. Airway injuries after one-lung ventilation: a comparison between double-lumen tube and endobronchial blocker. *Anesthesiology* 2006; **105**: 471–7
9. Sandberg WS. Endobronchial blocker dislodgement leading to pulseless electrical activity. *Anesth Analg* 2005; **100**: 1728–30
10. Campos JH, Hallam EA, Van Natta T, Kernstine KH. Devices for lung isolation used by anesthesiologists with limited thoracic experience. *Anesthesiology* 2006; **104**: 261–6
11. Ng A, Russell W. High frequency jet ventilation. *CPD Anaesth* 2004; **6**: 68–72

Please see multiple choice questions 16–19.